

MRCPUK

Exam SEND

SEND - Endocrinology and Diabetes (Specialty Certificate Examination)

Version: 6.0

[Total Questions: 200]

Question No : 1

Carbimazole is routinely used in the management of thyroid disease.

What does carbimazole inhibit?

- A. deiodinase type 1
- B. presentation of thyroid antigens to autoreactive T cells
- C. sodium/iodide symporter
- D. thyroglobulin synthesis
- E. thyroid peroxidase

Answer: E

Question No : 2

A 28-year-old Asian woman was seen in the joint diabetes-antenatal clinic at 16 weeks' gestation. She gave a history of gestational diabetes during her previous pregnancy. She had a strong family history of diabetes mellitus. She was fit and well, and had no symptoms other than slight early morning sickness.

According to NICE guidance (NG3, February 2015) for management of pregnancy, what is the most appropriate way to screen for gestational diabetes in this woman?

- A. 2-h postprandial plasma glucose
- B. fasting plasma glucose
- C. haemoglobin A1c
- D. oral glucose tolerance test as soon as possible
- E. oral glucose tolerance test at 24–28 weeks' gestation

Answer: D

Question No : 3

A 33-year-old woman, who was 9 weeks into her first pregnancy, was admitted with prolonged vomiting and secondary dehydration. She had lost 6 kg in weight since becoming pregnant. There was a strong family history of thyroid disease: two sisters were hypothyroid and one brother had required radioactive iodine for Graves' disease.

On examination, she had a smooth, small goitre. Her pulse was 94 beats per minute and her blood pressure was 104/42 mmHg. There was a tremor of the outstretched hands. Urinalysis was normal.

Investigations:

serum sodium 143 mmol/L (137–144)

serum potassium 4.4 mmol/L (3.5–4.9)

serum creatinine 105 μ mol/L (60–110)

serum thyroid-stimulating hormone (TSH) <0.01 mU/L (0.4–5.0)

serum free T4 24.0 pmol/L (10.0–22.0)

serum free T3 11.0 pmol/L (3.0–7.0)

A TSH receptor antibody concentration was awaited.

In addition to rehydration, what is the most appropriate next step in the management of her abnormal thyroid function?

- A. carbimazole
- B. labetalol
- C. observation
- D. propranolol
- E. propylthiouracil

Answer: C

Question No : 4

A 25-year-old man presented with a 2-month history of thirst and polyuria. He had minimal weight loss and his body mass index was 26 kg/m² (18–25). He had had sensorineural deafness since childhood. There was a very strong family history of sensorineural deafness and type 2 diabetes mellitus.

Urinalysis showed no ketones.

Investigations:

random plasma glucose 18.0 mmol/L

What is the most appropriate next step in management?

- A. genetic testing for maturity-onset diabetes of the young
- B. measurement of glutamic acid decarboxylase antibodies
- C. test for HFE genotype
- D. test for mitochondrial diabetes
- E. water deprivation test to assess posterior pituitary function

Answer: D

Question No : 5

A 34-year-old woman with a 21-year history of type 1 diabetes mellitus had started treatment with subcutaneous insulin pump therapy 18 months previously. Her haemoglobin A1c before starting pump therapy was 77 mmol/mol (20–42) and she had experienced severe hypoglycaemic events without warning symptoms over the previous 4 years.

At review in clinic, she reported continuing episodes of severe hypoglycaemia without warning symptoms despite regular monitoring and advice from her insulin pump nurse specialist.

On examination, her blood pressure was 134/80 mmHg and fundoscopy revealed moderate background diabetic retinopathy. Examination of the feet revealed strong, palpable pedal pulses and early evidence of sensory neuropathy.

Investigations:

estimated glomerular filtration rate (MDRD) 24 mL/min/1.73 m² (>60)

haemoglobin A1c 56 mmol/mol (20–42)

24-h urinary total protein 2.3 g (<0.2)

What is the most appropriate next step in management?

- A. change to intensified subcutaneous insulin injections
- B. refer for allogeneic pancreas transplantation
- C. refer for allogeneic pancreatic islet cell transplantation
- D. refer for combined pancreas and kidney transplantation
- E. refer for continuous glucose monitoring

Answer: D

Question No : 6

A 42-year-old woman, with type 1 diabetes mellitus of 22 years' duration, attended for annual review. She was using biphasic insulin twice daily and taking aspirin 75 mg, simvastatin 40 mg and ramipril 10 mg daily.

On examination, her blood pressure was 164/87 mmHg.

Investigations:

serum potassium 5.9 mmol/L (3.5–4.9)

serum creatinine 197 μ mol/L (60–110)

estimated glomerular filtration rate (MDRD) 26 mL/min/1.73 m² (>60)

haemoglobin A1c 72 mmol/mol (20–42)

urinary albumin:creatinine ratio 27.0 mg/mmol (<3.5)

urine culture negative

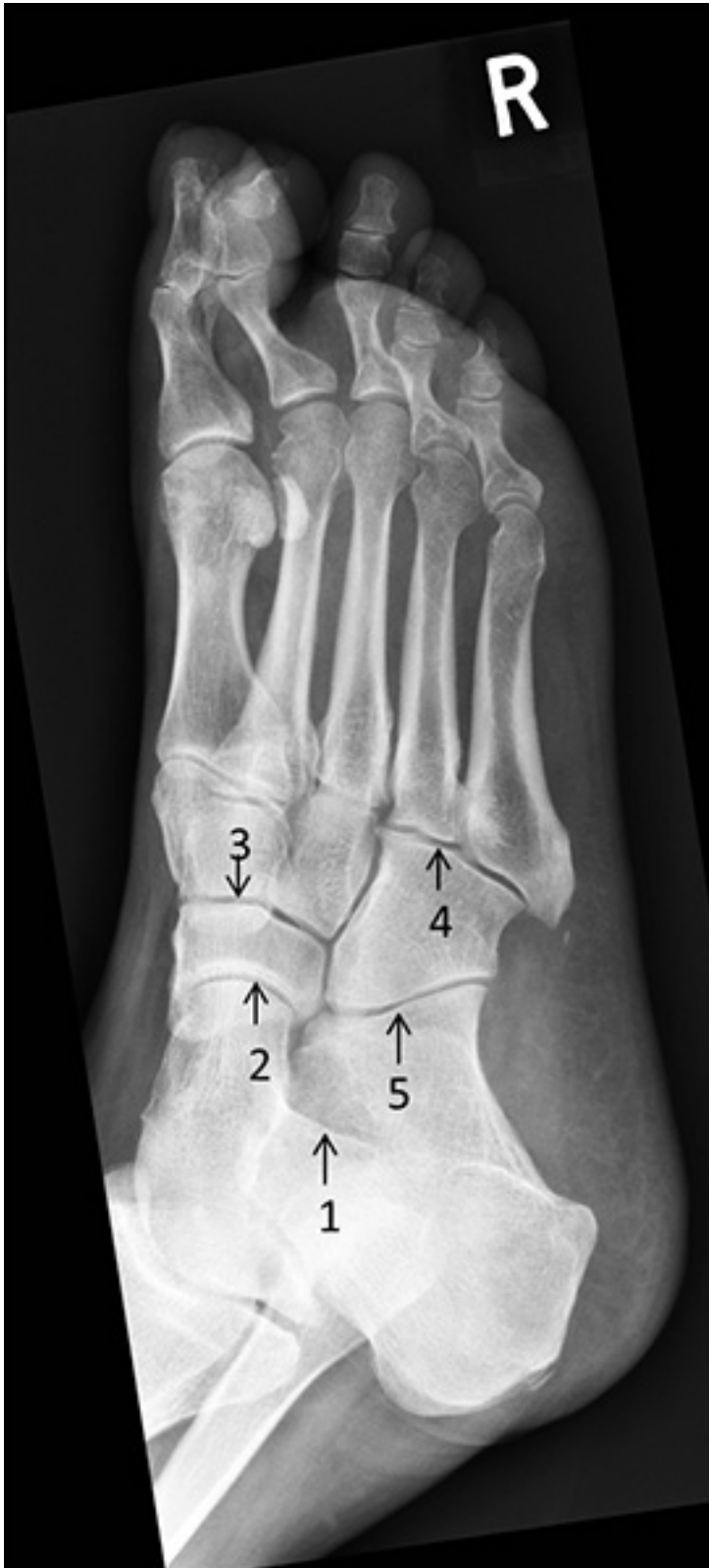What is the most important next step in management?

- A. add aliskiren
- B. add furosemide
- C. change to intensive insulin regimen
- D. check bicarbonate
- E. refer to a nephrologist

Answer: E

Question No : 7

A 55-year-old man with type 2 diabetes mellitus presented with foot swelling and discomfort. He had a peripheral sensory neuropathy attributed to diabetes mellitus. A midfoot Charcot's arthropathy was suspected, and a plain X-ray was arranged (see image).



Which is the talonavicular joint?

- A. 1
- B. 2
- C. 3
- D. 4
- E. 5

Answer: B

Question No : 8

A 54-year-old woman attended clinic for routine follow-up. She had Cushing's syndrome secondary to ectopic adrenocorticotrophic hormone syndrome with no primary source identified.

She had declined bilateral adrenalectomy. Routine medication included metyrapone 500 mg three times daily, ketoconazole 200 mg once daily and hydrocortisone 10 mg in the morning and 5 mg in the evening.

Metyrapone inhibits the action of which enzyme in steroidogenesis?

- A. 3 β -hydroxysteroid dehydrogenase
- B. 5 α -reductase
- C. 11 β -hydroxylase
- D. 17 β -hydroxylase
- E. 21-hydroxylase

Answer: C

Question No : 9

A 76-year-old man with a 17-year history of type 2 diabetes mellitus attended for his annual review. Comparison of his retinal screening report with the previous year's report showed that his visual acuity was unchanged at 6/9 in both eyes. The previous year's right eye retinal image had been reported as 'pre-proliferative retinopathy', whereas this year's was reported as 'pre-proliferative retinopathy with maculopathy'.

What is the most appropriate next step?

- A. routine referral to an ophthalmologist
- B. routine re-screen in 6 months
- C. routine re-screen in 12 months
- D. urgent referral to an ophthalmologist within 2 weeks
- E. urgent re-screen within 2 weeks

Answer: A

Question No : 10

A 32-year-old woman presented to the outpatient clinic with a 1-year history of amenorrhoea that began after stopping her oral contraceptive pill. She had previously had two successful pregnancies and was otherwise well.

Examination was normal and no visual field defect was present on testing to confrontation.

Investigations:

serum sodium 138 mmol/L (137–144)

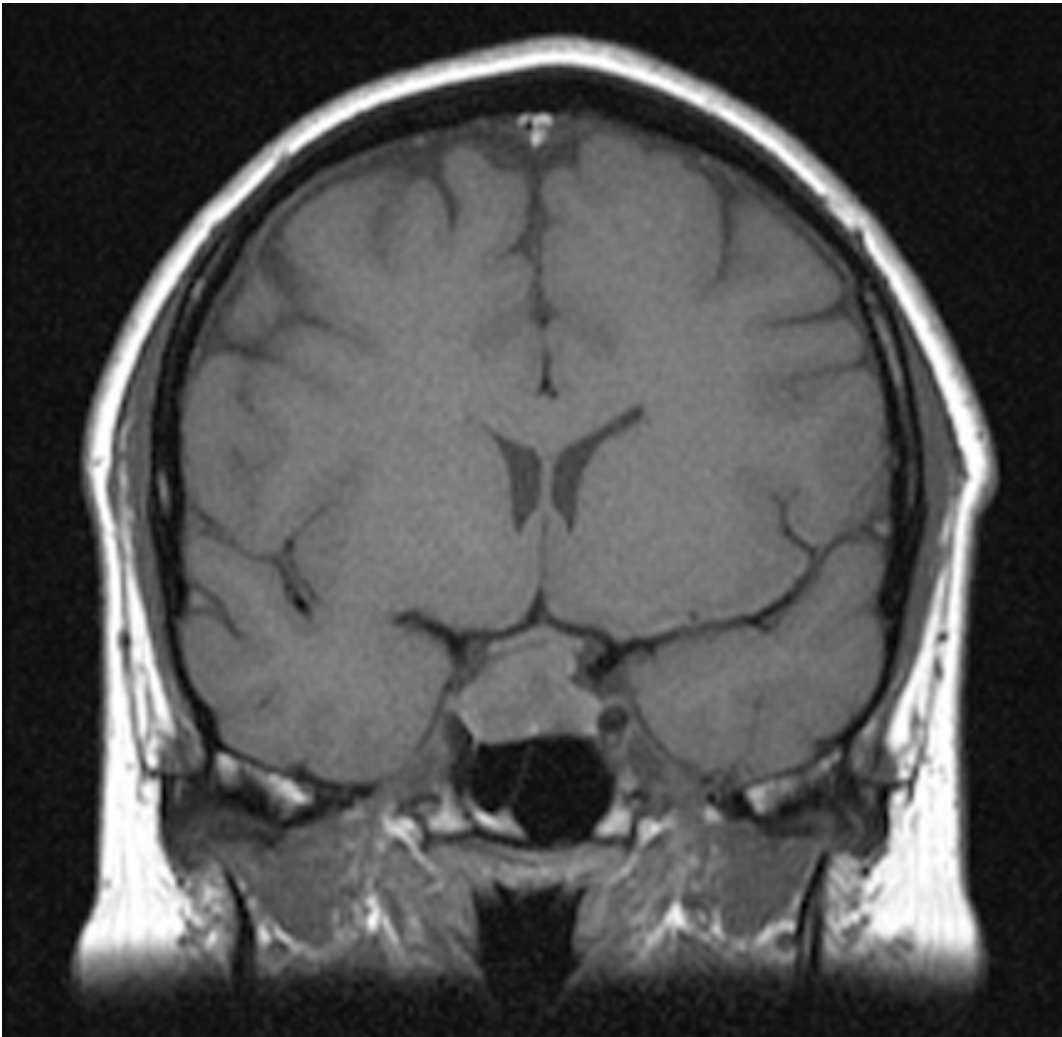
serum potassium 3.8 mmol/L (3.5–4.9)

plasma follicle-stimulating hormone 2.0 U/L (2.5–10.0)

plasma luteinising hormone 2.0 U/L (2.5–10.0)

serum prolactin 1050 mU/L (<360)

MR scan of pituitary see image



What is the most appropriate treatment?

- A. bromocriptine
- B. cabergoline
- C. octreotide
- D. pituitary surgery
- E. stereotactic pituitary radiosurgery

Answer: D

Question No : 11

A 32-year-old man presented with medullary thyroid cancer, treated by total thyroidectomy. He had a past history of primary hyperparathyroidism, treated by selective parathyroidectomy. Postoperatively, plasma calcitonin was undetectable and serum calcium was in the normal range.

Investigations:

RET genotype heterozygote codon 634 C>T mutation

What is the most appropriate approach to annual screening for pheochromocytoma?

- A. biochemical screening
- B. CT scan of adrenal glands
- C. MIBG scanning
- D. MR scan of adrenal glands
- E. octreotide scanning

Answer: A

Question No : 12

A 46-year-old Afro-Caribbean man with sarcoidosis was found to have hypercalcaemia and was treated with prednisolone 20 mg/day. Within 3 weeks his serum calcium had fallen to within the reference range.

How do glucocorticoids reduce serum calcium in sarcoidosis?

- A. direct calcium shift into cells
- B. increase intravascular fluid volume
- C. promote urinary calcium excretion
- D. reduces extrarenal 1- α -hydroxylase activity
- E. suppress parathyroid hormone secretion

Answer: D

Question No : 13

A 59-year-old man with an 8-year history of type 2 diabetes mellitus was seen in the outpatient clinic. He had worsening renal function in the absence of microalbuminuria.

On examination, his blood pressure was 175/90 mmHg. He had a femoral bruit, and absent dorsalis pedis pulses bilaterally.